



## Summary Feedback

(Combined feedback broadcasted at multiple times this week)

### PRE-RECORDED: Basildon FRCR 2B 'A to Zee' Course 2020

## Session 4/40

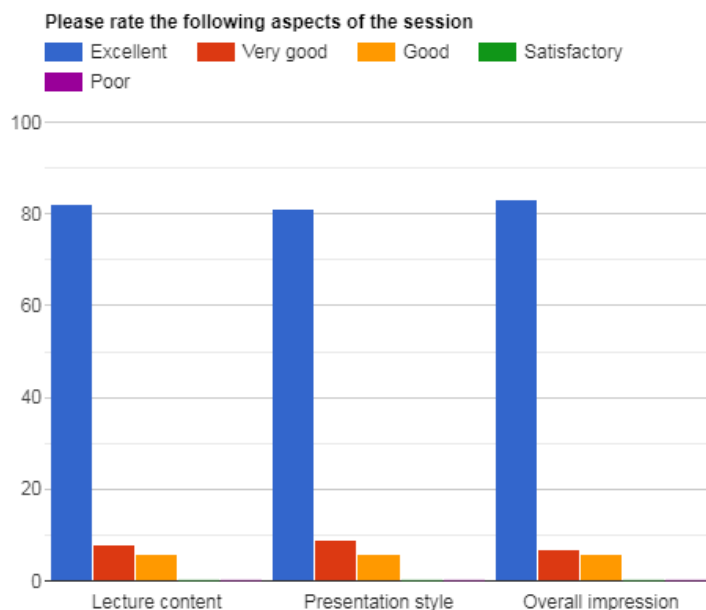
### Chest & Cardiac Imaging For FRCR - Part 2

(25<sup>th</sup> and 26<sup>th</sup> May 2024)

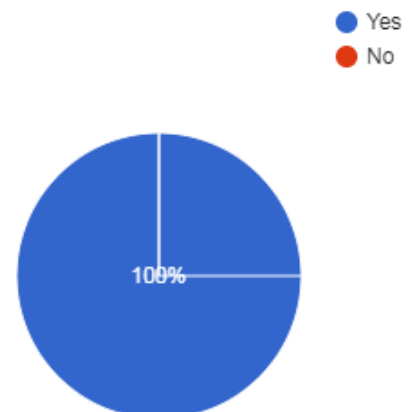
Lecturer: Alexia Farrugia

#### Summary Points:

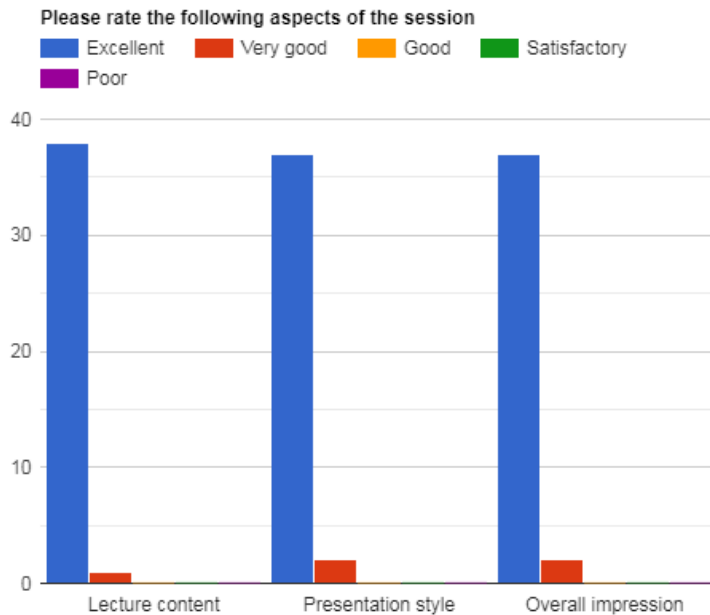
- Total Attendees: 423 from 37 Countries (Algeria, Australia, Bahrain, Bangladesh, Czech Republic, Dominica, Egypt, Ghana, Hong Kong, India, Indonesia, Iraq, Jordan, Kenya, Libya, Malaysia, Malta, Myanmar, Nepal, Nigeria, Oman, Pakistan, Poland, Qatar, Saudi Arabia, Singapore, South Africa, Sri Lanka, Sudan, Swaziland, Türkiye, UAE, UK, Ukraine, Yemen, Zambia, Zimbabwe).
- Total duration: 2 hours (each session broadcasted thrice during the week)
- Total feedback received from 147 participants, from three different broadcasts



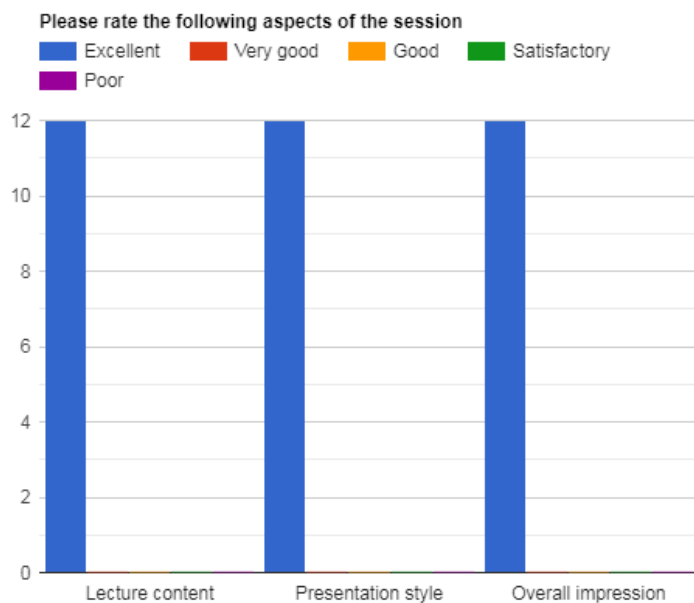
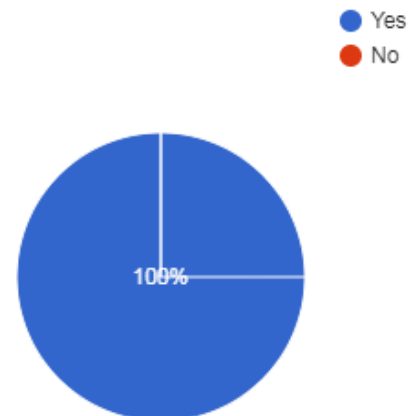
Did you find it useful  
96 responses



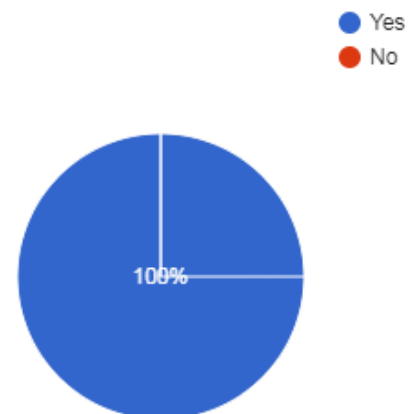
## Chest & Cardiac Imaging For FRCR - Part 2



Did you find it useful  
39 responses



Did you find it useful  
12 responses



## Testimonials

- Excellent. Worth watching and well put together (UK).
- Lecture was excellent and covering exam oriented topics (India).
- Very nice exam cases, beautifully explained by Dr Alexia Farrugia. Thank you! (Pakistan).
- Very nice cases and excellent explanation of imaging findings by the presenter (UK).
- Going through cases viva style is useful to know how pathology corresponds on imaging (UK).
- Variety of cases, excellently explained. Really loved the take-home points (Pakistan).
- The explanations provided by the tutor were most valuable(UK).
- The immediate lecture notes after the viva is extremely useful and affirming (Malaysia).
- Cases were great. Great explanations and slides (UK).
- Very informative session (India).

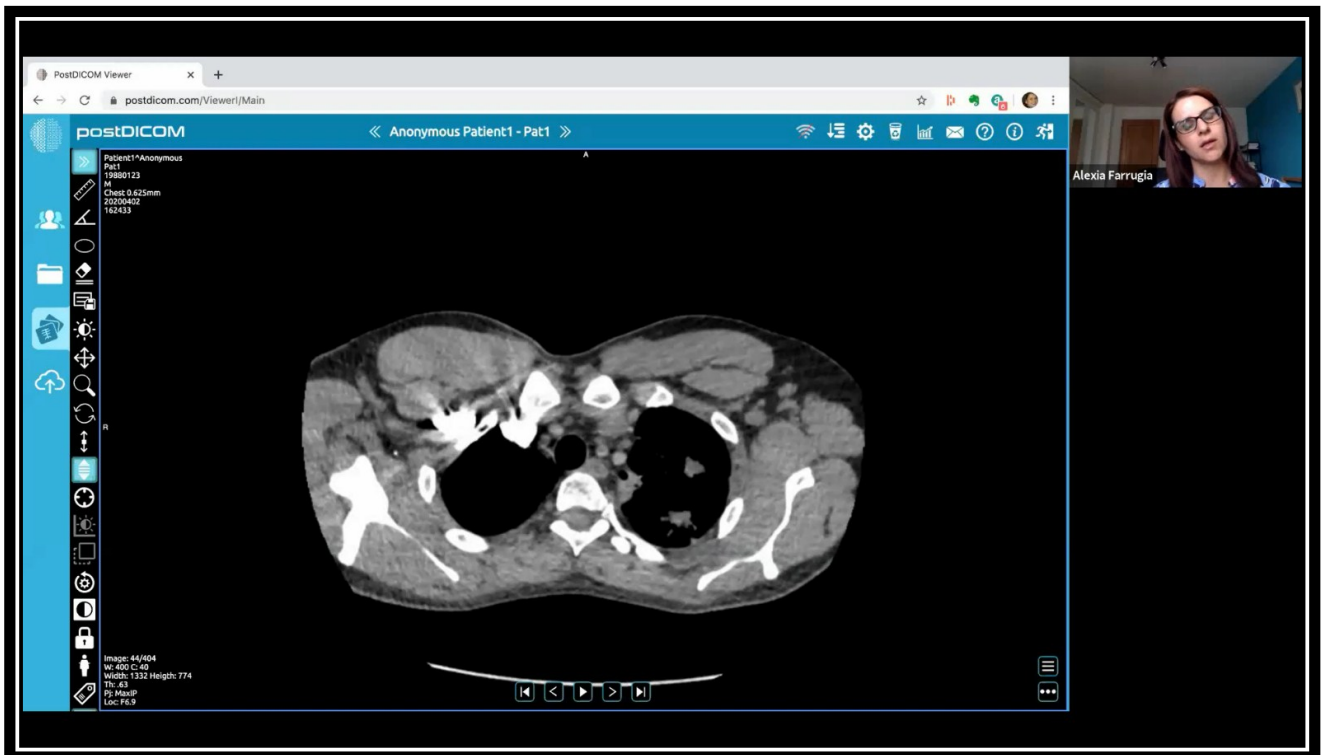
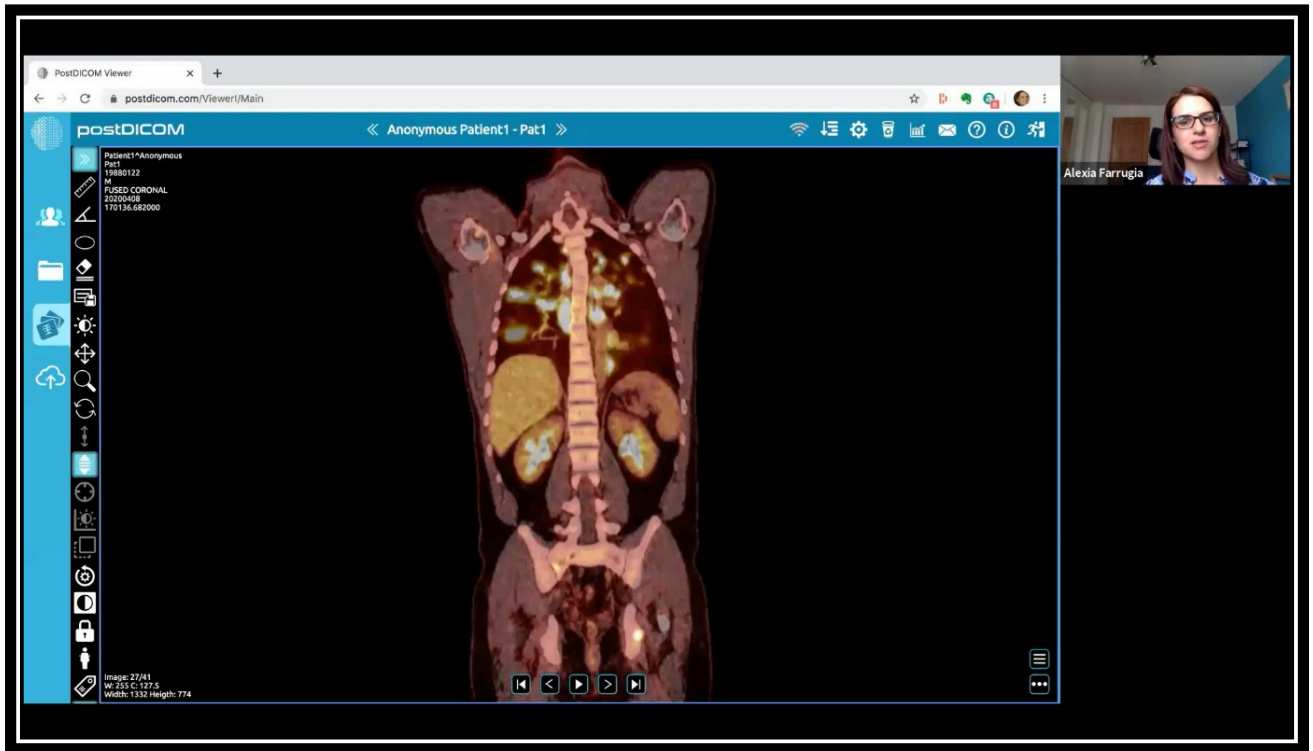
## Chest & Cardiac Imaging For FRCR - Part 2

- Excellent resource (India).
- Very interesting findings and cases (UK).
- Excellent teaching cases (Iraq).
- Good selection of cases (Egypt).
- Covers most important chest exam cases (Libya).
- Cases and description of cases after case completion were very good (Pakistan).
- Simple explanation was most useful (Türkiye).
- Recaps all the aspects of cardiovascular and chest topics through Q&A was most useful (Sri Lanka).
- The power point slides explanations on each cases was most useful (Nigeria).
- Case discussion was most useful (India).
- Very good revision cases (India).
- Excellent teaching (Sri Lanka).
- Collection of cases was most useful (Sri Lanka).
- Image presentation was most useful (Nigeria).
- Lecture content was most useful (Nigeria).
- I liked the teaching points with good images (India).
- Very good lecture, learnt a lot from the cases (Pakistan).
- The host taking viva in a nice encouraging way (Pakistan).
- The variety of cases shown in both CXR and CT. Addition of CMRI and PET for some cases were most useful (Pakistan).
- The explanations were useful (Nigeria).
- Excellent cases (Malaysia).
- Excellent collection and detailed feedback (UK).
- Good viva cases (Zimbabwe).
- The cases and discussion were most useful (Egypt).
- Nice cases (Pakistan).
- Key explanation after each case was most useful (UK).
- Good cases and teaching, informative slides after every cases (Pakistan).
- Cases and explanation was most useful (Pakistan).
- Well devised lecture (Pakistan).
- Cases and explanation were most useful (Sri Lanka).
- I liked the variation of cases in chest imaging (Pakistan).
- It was perfect (UAE).
- Interesting cases and feedback and review (Algeria).
- Cases and concise description was most useful (India).
- Excellent session (Malaysia).
- Good cases (India).
- Teaching material was most valuable (UAE).
- Very enlightening cases (UK).
- Good cases (Qatar).
- Very good lecture (India).
- The cases were very good (Malaysia).
- Excellent cases (Sri Lanka).
- Excellent teaching today (UK).
- Everything is excellent (Saudi Arabia).
- It was perfect (UAE).
- Very useful (Pakistan).

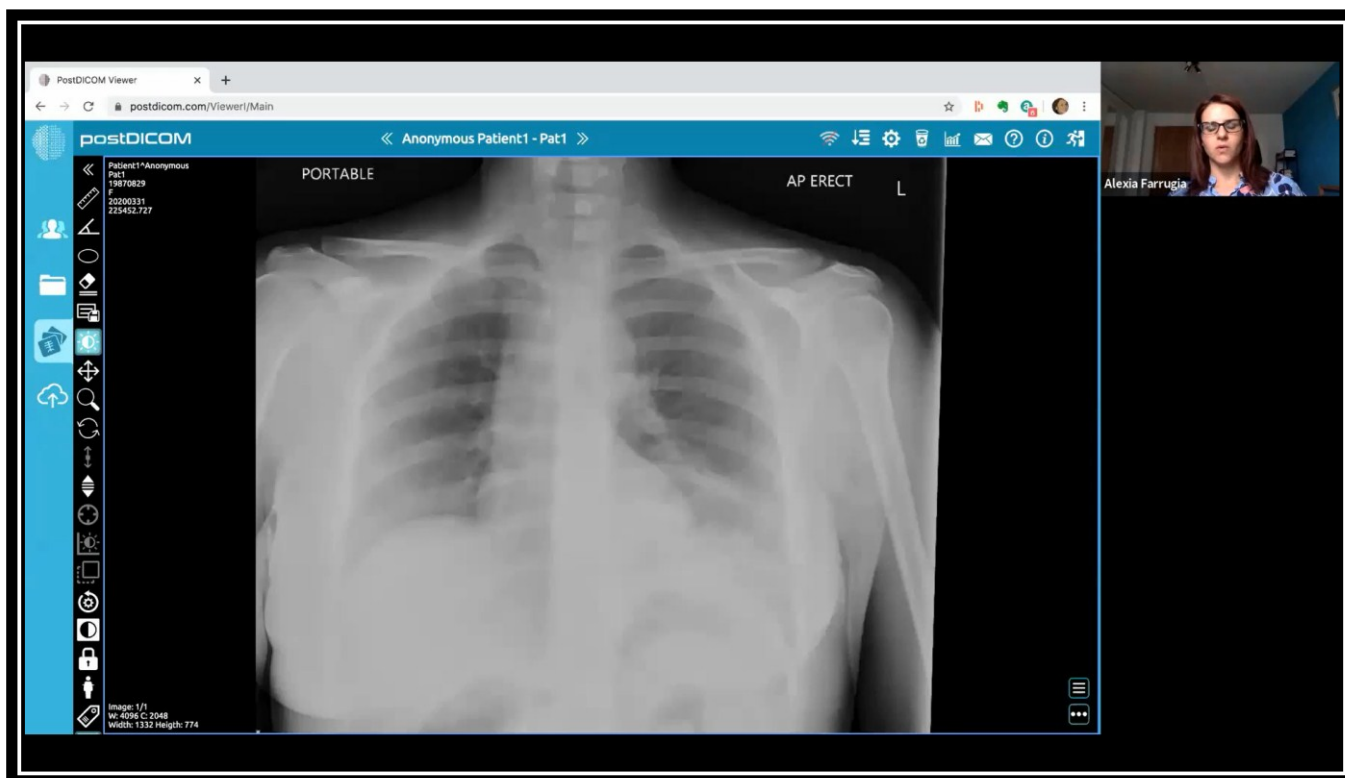
## Chest & Cardiac Imaging For FRCR - Part 2

- Good classes (India).
- Super (India).
- All very informative (UAE).
- Excellent, thanks for your great effort (Yemen).
- Very educative (Nigeria).
- Woow (Egypt).
- Great session (Algeria).
- Excellent session. Thank you (Malaysia).
- Very informative (India).
- Fantastic (Malaysia).
- Superb session (India).
- Valuable (India).
- Excellent cases (UK).
- Crux points in the end by teacher were most useful (Pakistan).
- Focused teaching (Malta).
- Images and presentation skills were most useful (Sri Lanka).
- Helpful detailed explanations of cases were most valuable (UK).
- Case mix which followed by differential diagnosis and brief justification was most useful (Malaysia).
- Little key points of every case was most useful (Pakistan).
- Making the initial diagnosis with CXR and linking the findings with CT thorax were most useful (Sri Lanka).
- Good discussion (Malaysia).
- The CT images, discussion and differentials diagnosis were excellent (Kenya).
- Good cases and discussion (UK).
- I liked the cases and discussion (Saudi Arabia).
- All aspects were useful (Saudi Arabia).
- The host taking viva in a nice encouraging way (Pakistan).
- Great cases (UK).
- Nice cases shown (Pakistan).
- All aspects were useful (Pakistan).
- The case based discussion was very concise with summaries of expected findings (Nigeria).
- Wonderful (Malaysia).
- Very interesting and informative (Saudi Arabia).
- Very informative (Pakistan).
- Very good cases and detailed explanation of pathology (Pakistan).
- Very good effort! (UK).
- I find the whole lecture useful (Pakistan).
- Very nice description (Pakistan).

# Chest & Cardiac Imaging For FRCR - Part 2



# Chest & Cardiac Imaging For FRCR - Part 2



=====XX=====XX=====